

Disease Extension in Active Chronic Otitis Media

Maroof Saki Baki¹, Ali Hussein Jamal², Ayad Mustafa Bahaaldin³

^{1,2}ENT Specialist in Azadi Teaching Hospital

³ENT Specialist in Kirkuk General Hospital

DOI: [10.32894/kjms.2022.135653.1032](https://doi.org/10.32894/kjms.2022.135653.1032)

Abstract:

- **Background:** Active chronic otitis media present with multiple findings within the middle ear like, granulation tissue and cholesteatoma which has extension and origin from similar pathological conditions within the attic and mastoid air cell system.
- **Objectives:** to assess the operative finding in middle ear cleft including the attic and air cells during mastoid exploration.
- **Material and Method:** Prospective study
Setting: E.N.T department Kirkuk and Azadi Teaching Hospitals
Patient's selection: 20 Ears; on whom decision of mastoid exploration was taken.
Extensions of granulation tissue and cholesteatoma assessed.
- **Results:** 60% belonged to active mucosal COM with granulation tissue found in the mastoid cavity. 40% belonged to active squamous COM with cholesteatoma and granulation tissue found in the mastoid air cell system.
Aural polyp found with extensive mucosal disease, bone erosion and 50% associated with cholesteatoma.
- **Conclusion:** Active mucosal chronic otitis media was found more frequently during mastoid exploration in the selected ears for our study.

Keywords: Chronic Otitis Media, cholesteatoma, granulation tissue.

INTRODUCTION

Active Chronic Otitis Media [6] where there is inflammation and the production of pus . A decision as to whether an ear is currently active is primarily based on visualization of an inflamed mucosa and secretions. In squamous epithelial disease that is active with a cholesteatoma, there is almost invariably associated mucosal disease that can be seen and produces the secretions, perhaps along with squamous epithelial debris. Secretions, and in particular mucopus, can dry and be mistaken for wax. Once removed, the underlying disease may still be active or have become inactive. **Active mucosal COM: Activity** is evident, usually with a generally inflamed middle ear mucosa, but sometimes with granulation tissue that is localized and which can become polypoidal . In both active and inactive COM, particularly when the defect involves the posterior third, the intactness or otherwise of the ossicular chain should be assessed and recorded. **Active squamous COM (Cholesteatoma)** Cholesteatomas are the end stage of squamous epithelial retractions of the pars tensa or flaccid that are not self- cleansing, retain epithelial debris and elicit a secondary, inflammatory mucosal reaction. In the majority of cases the extent of the cholesteatoma cannot be determined otoscopically because the retraction pocket clearing of debris is not fully in view[6].

- Active mucosal COM group (perforation with otorrhoea with mucosal changes including granulation tissue and aural polyp).
- Active squamous COM group (Cholesteatoma). The results arranged as:

MATERIALS AND METHODS

Study design: Prospective study.

Setting: Department of otolaryngology / Kirkuk and Azadi Teaching Hospital.

Patients' selection: during the period from January 2013 to February 2019,

20 Ears of 20 patients (12 females and 8 males) having active chronic otitis media needed mastoid exploration were studied.

Age of the patients ranged from 5 to 46 years.

Based on clinical otomicroscopic examination these 20 active ears categorized into 2 groups

□ Active mucosal COM group (perforation with otorrhoea with mucosal changes including granulation tissue and aural polyp).

1. The clinical otomicroscopic observations preoperatively
2. Surgical findings during mastoid exploration

The findings included the presence and extension of granulation tissue and cholesteatomas and their extension.

RESULTS

Diagnostic Categories : based on clinical otomicroscopic examination; the 20 ears involved in this study categorized into 2 main groups.

□ Active mucosal com group: 12 ears (12/20; 60%)

Including 2 Ears with aural polyp (2/12; 17%)

▪ Overall incidence of aural polyp in this study is (2/20; 10%)

□ Active squamous com group: 8 ears (8/20; 40%).

20 patients with active chronic otitis media included in this study 12 (60%) females and 8 (40%) males.

□ Active squamous COM group (Cholesteatoma).

The results arranged as:

Their ages range was (5 – 46 years) with mean age of (22.30 years).

Mean age of incidence for females were 20 years.

Mean age of incidence for males were 25.75years.

□ Active mucosal com group:

- Age range was (5 – 46 years)

- Mean age (26.08 years)

- Active squamous com group:

- Age range was (5 – 32 years)

- Mean age was (16.6 years).

- ▶ All patients:

- Ages range was (5 – 46 years)

- Mean age was (22.30 years).

- Paediatric age group

- Active mucosal com group: 3 /12 (25%)

- Active squamous com group: 4/8 (50%)

- ▶ Overall: 7/20 (35%) children 15years old and younger.

- side of the involved ear

- Left ear involved in 60% (12/20Ears).

- Right ear involved in 40% (8/20Ears).

- pathological tissue in the middle ear

- Active mucosal com group:

- Profuse mucopurulent discharge and inflamed middle ear mucosa found in all ears with or without the following:

- Granulation tissue in 8 Ears (66%)

- Polypoid middle ear mucosa in 2 Ears (17%)

- Aural polyp in 2 Ears (17%)

- Active squamous com group:

- Cholesteatoma alone found in 6 Ears (75%)

- Cholesteatoma with granulation tissue in 2 Ears (25%)

■ Operative findings

■ Mastoid cortex (table 3.7)

□ Active mucosal com group:

- Cellular in 7 (58%)
- Sclerosed in 5 (42%)

□ Active squamous com group:

- Sclerosed in 6 (75%)
- Cellular in 2 (25%)

▶ Overall: Mucopurulent discharge found in all involved ears.

The main pathological changes found were:

- Sclerosed in 11 (55%)
- Cellular in 9 (45%)

■ Pathological tissue and its extension

■ Mastoid air cell system

□ Active mucosal com group:

- Granulation tissue was present in 12 Ears (100%)
- Cholesteatoma was present in 1 Ear (8.3%) (In association with aural polyp)

□ Active squamous com group:

- Cholesteatoma was present in all Ears (8/8; 100%) of this category.
- Granulation tissue present in all Ears (8/8; 100%) with cholesteatoma.

■ fossa incudis:

□ Active mucosal com group:

- Granulation tissue was present in 11 Ears (91.6%)
- Cholesteatoma was present one Ear (1/12; 8.3%) in ear with aural polyp.

□ Active squamous com group:

- Cholesteatoma was present in all Ears (8/8; 100%)
- granulation tissue with cholesteatoma in 5 Ears (50%)

■Attic

□Active mucosal com group:

- Granulation tissue found in 11 Ears (91.6%) Cholesteatoma found in one (8.3%) Ear (in association with aural polyp).

□ Active squamous com group:

- Cholesteatoma was present in all Ears (100%)
- Granulation tissue with cholesteatoma in 5 Ears (62.5%)

□ **Supratubal recess (anterior epitympanic recess)**

□active mucosal com group:

- Granulation tissue found in 3 Ears (42%)
- Cholesteatoma found in one (8.3%) Ear (In association with aural polyp).

□ active squamous com group:

- Cholesteatoma was present in 4 Ears (50%)

► Overall: pathological tissue was present in supratubal recess in 8 Ears (40%)

■Facial recess

Active Mucosal COM group

- Granulation tissue found in 7 (58.3%) Ears
- Cholesteatoma found in 1 Ear (8.3%) (In association with aural polyp)
- Active squamous com group:
- Granulation tissue found in 5 Ears (62.5%).
- Cholesteatoma was present in 8 Ears (100%).

► Overall:

- Granulation tissue found in facial recess in 12Ears (60%).
- Cholesteatoma found in facial recess in 9Ears (45%).

■Sinus tympani

□active mucosal com group:

- Cholesteatoma was present in 1 Ear in association with aural polyp (8.3%)

□ Active squamous com group:

- Cholesteatoma was present in 4 Ears (50%)

► Overall: cholesteatoma was present in sinus tympani in 5 Ears

(25%) :

■Middle ear cavity

□Active mucosal com group: Granulation tissue found in all (100%) Ears

□ Active squamous com group: Cholesteatoma found in all (100%) Ear.

Table 1 Distribution of patients according to otoscopic diagnostic category

Otosopic diagnostic category	NO.	%
Active mucosal COM	12	60%
Active squamous COM (cholesteatoma)	8	40%
total	20	100%

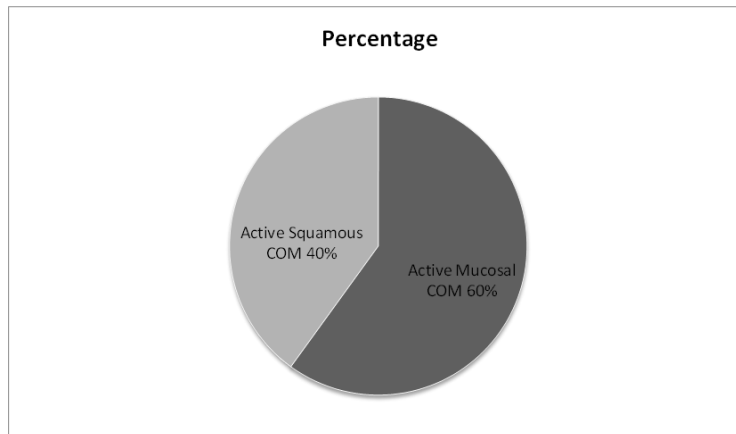


Figure 1 Percentage of Otoscopic diagnostic abnormal results

Table 2: Active mucosal group

Mast. Cortex	Mastoid Antrum	Retrofacial aircells	Attic	Supratubal recess	Middle ear	Sinus tympani
sclerosed	Granulation tissue	gt	gt	-	gt	-
sclerosed	gt	gt	gt	-	Polypoid mucosa	-
Cellular	gt	gt	gt	-	gt	-
sclerosed	gt	gt	gt	-	Polypoid mucosa	-
Cellular	Ch+gt	gt	Ch+gt	Ch	Polyp	Ch
Cellular	gt	gt	gt	-	gt	-
sclerosed	gt	gt	gt	-	gt	-
Cellular	gt	gt	gt	-	gt	-
Cellular	gt	gt	gt	-	gt	-
Cellular	gt	gt	gt	-	gt	-
sclerosed	gt	gt	gt	gt	gt	-
Cellular	gt	gt	gt	gt	gt	-

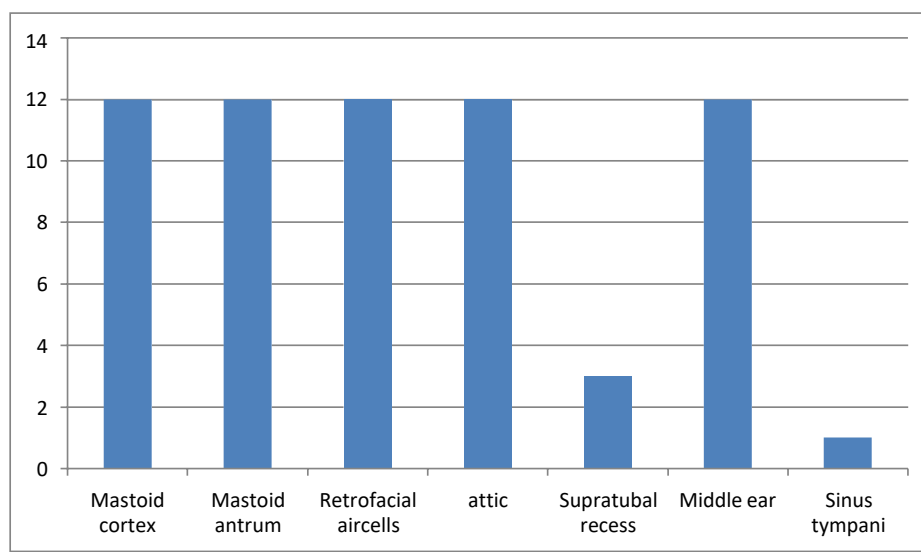
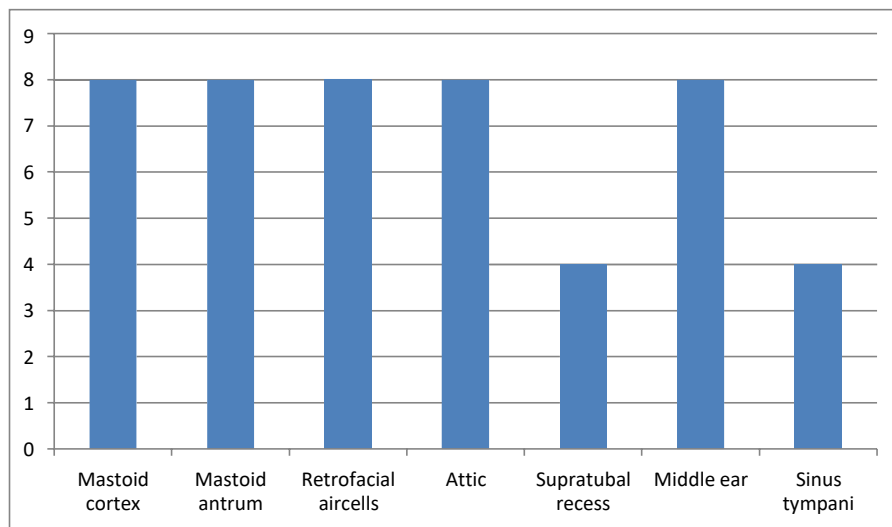


Table 3 Active squamous group

Mastoid Cortex	Mastoid Antrum	Retrofacial aircells	Attic	Supratubal recess	Middle ear	Sinus tympani
Sclerosed	Ch+gt	Granulation tissue	Ch+gt	-	Ch	-
Sclerosed	Cholesteatoma	Granulation tissue	Ch+gt	Ch	Ch	Ch
Sclerosde	Cholesteatoma	Granulation tissue	gt	Ch	Ch	Ch
Cellular	Cholesteatoma	Granulation tissue	gt	Ch	Ch	Ch
Cellular	Cholesteatoma	Granulation tissue	gt	Ch	Ch	Ch
Sclerosed	Ch+gt	Granulation tissue	Ch+gt	-	Ch	-
Sclerosed	Ch+gt	Granulation tissue	Ch+gt	-	Ch	-
Sclerosed	Ch+gt	Granulation tissue	Ch+gt	-	Ch	-



DISCUSSION

Pathological conditions within the middle ear usually have a connection or extension within hidden areas in the epitympanum and mastoid air cells. These areas are not visualized through the tympanic membrane, therefore; exploration is mandatory to discover this connection.

These pathological changes clinically expressed either as mucopurulent discharge, polyp or granulation tissue or cholesteatoma.

Discharge through a perforation is usually due to extensive cellular inflammation and infiltration within the entire middle ear cleft including the mastoid antrum (chronic mastoiditis). Polyp or granulation tissue usually have a root of origin either within the anterior and posterior epitympanic recesses, the epitympanum, or originate from areas which is hidden within mastoid air cell system. Cholesteatomas which appear either in the attic or in the middle ear originates or have extension either in the epitympanic recesses or in the mastoid air cell system, therefore; it should be cleared from there.

Surgical exploration will delineate the disease extension or origin and its eradication from the hidden and inaccessible areas in the entire middle ear cleft including mastoid air cell system, the attic, anterior and posterior epitympanic recesses, the sinus tympani.

The 20 Ears with active COM necessitating mastoid exploration involved in this study grouped, the results documented and tabulated as two categories.

Unfortunately we didn't find other similar studies as 2 category groups according to this new definition and classification to compare all our results. Few studies carried common elements; we obtained few comparable results of certain clinical and surgical findings.

■ definition and categories

- in this study the term “active com”; where there is inflammation and pus, categorized otoscopically into active mucosal com and active squamous com (cholesteatoma)[6].

▫ these terms equate the classic term “chronic suppurative otitis media” without or with cholesteatoma [14].

▫ com without cholesteatoma and com with cholesteatoma [15]

▫ nccom (noncholesteatomatous com) and comc (cholesteatomtous com) [16]

■ incidence of active mucosal & active squamous com necessitating mastoid exploration

- ▶ in this study

- active mucosal com: 60%.

- active squamous com: 40%.

- ◊ oswaldo laercio's study [16] of 84 ears with active com:

- nccom: 49%.

- comc: 51%.

- ◊ al-badri, yousif elamien [17]

- mucosal disease: 51.9%

- cholesteatoma: 48.1%

■ sex

- ▶ in this study, overall patients involved:

- 60% females

- 40% males

- ◇ al-badri, yousif elamien's study

[17]:

- 55.6% females

- 44.4% males

- ◇ al-badri, ali kamal's study ^[18]:

- 45.8% females

- 54.2% males

mean age of incidence

in this study: 22.30 years over all patients

al-bedri, yousif elemien's study

^[17]: 23.7 years over all patients.

in this study:

active mucosal com group: age range was (5 – 46 years) mean age (26.08 years) active

squamous com group: age range was (5 – 32 years) mean age of incidence for active

squamous com was 16.6years.

The mean age and the upper age limit was higher in active mucosal group.

this is most probably due to patient's tolerance to ear discharge.

mean age of presentation is lower in active squamous group probably due to

1. more annoying symptoms.
2. inability to clean the deeply seated scanty thick discharge.

▣ paediatric age group

- ▶ in this study, 35% overall studied group were children 15 years and younger age

- ◇ 12.5% in al-badri, yousif elamien's study ^[17]

- ◇ 14.8% in al-badri, ali kamals's study ^[18]

- in this study, paediatric age group formed (50%) in squamous group compared to 25% in the mucosal group.

▫this can be attributed to the more disabling and complicating nature of the disease.

▣ side of the involved ear

- ▶ in this study: 60% involved the left and 40% involved the right ear

- ◊ al-bedri, yousif elameen: 59.3% in the left and 40.7% involved the right ear ^[17]

- in this study the operation involved the better hearing ear in one patient with bilateral active mucosal com.

▫the non- operated ear had intermittent discharge with small central perforation and inflamed middle ear mucosa without granulation tissue or polyp. there was incudostapedial disconnection. pure tone audiometry revealed mixed deafness.

the sensorineural loss may be attributed to topical or systemic medication or may be attributed to noise exposure.

▣ Pathological tissue in the middle ear cleft

▣ Middle ear cavity

- ▶ In this study, mucosal changes found in all ears (100%) in the active mucosal groups.

Aural polyp reported in 2Ears (10%) in our study associated with posterior marginal perforation and massive extension of pathological tissue and bony erosion.

- ◊ Al-Badri Ali Kamal's study:

- Granulation tissue found in the middle ear in 95.4%Ears.

- Aural polyp reported in 2Ears (8.3%).

▣ Attic

▣ Active mucosal com group:

- In this study

- Granulation tissue found in 11 Ears (91.6%). Cholesteatoma found in one (8.3%) Ear (In association with aural polyp).

□ Active squamous com group:

- Cholesteatoma was present in all Ears (100%)
- granulation tissue with cholesteatoma in 5 Ears (62.5%)

▫ Al-Badri, Yousif elamien's study ^[17]

□ Granulation tissue found in the attic in 21.4% Ears

□ Cholesteatoma found in the attic in 31% Ears

■ Mastoid antrum

► In this study

□ Active mucosal com group: granulation tissue found in all ears.

□ Active squamous com group: cholesteatoma found in all ears.

- In extensive cholesteatoma, cholesteatoma sac found filling the mastoid antrum
- granulation tissue frequently found in retrofacial and perisinus cells.

◇ Al-Badri, Ali Kamal's study ^[18]: Granulation tissue was found in (91.6%) Ears

◇ Al-Badri Yousif elamien's study ^[17]:

▫ Extensive granulation tissue involving mastoid air cells found in 57.2% ears.

▫ Extensive cholesteatoma found in 46.2%.

Δ Larger proportion of our studied ears had extensive disease involving the middle ear and mastoid air system.

■ Aural polyp

► In this study, one of the two aural polyp (50%) associated with cholesteatoma.

◇ These findings are comparable with Thomas Prasannaraj^[19] and et al study (aural polyp safe or unsafe disease) in describing aural polyp as extensive mucosal disease and 35% associated with cholesteatoma.

□ Facial recess

► In this study:

▪ Granulation tissue found in facial recess in 14 Ears (70%).

▪ Cholesteatoma found in facial recess in 9 Ears (45%).

◇ Al-Badri, Yousif elameen ^[17]

□ Granulation tissue extension involving the facial recess found in 21.4% Ears

□ Cholesteatoma found in 23% Ears.

△ More frequent involvement of facial recess found in our study.

▫ This may indicate more advanced disease extension.

▫ May be attributed to later presentation.

□ Sinus tympani

□ Active mucosal com group:

• Cholesteatoma was present in 1 Ear in association with aural polyp (8.3%)

□ active squamous com group:

• Cholesteatoma was present in 4 Ears (50%)

◇ Overall: cholesteatoma was present in sinus tympani in 5 Ears (25%) No results had been mentioned in the available previous studies about involvement of this area.

■ Supratubal recess (Anterior epitympanic recess)

► In this study

□ Active mucosal com group:

▪ Granulation tissue found in 3 Ears (42%)

▪ Cholesteatoma found in one (8.3%) Ear (in association with aural polyp).

□ Active squamous com group:

▪ Cholesteatoma was present in 4 Ears (50%)

- ▶ Overall: pathological tissue was present in supratubal recess in 8 Ears (40%)
- ◇ Oswaldo et al ^[16]; considered involvement of this area an exception for canal wall up mastoidectomy.
- In our study, one patient (5 years age female) in active squamous group with involvement of supratubal recess managed by canal wall up technique.

CONCLUSION

1. Active chronic otitis media has pathological tissue extension into attic, mastoid antrum and mastoid air cells.
2. Cholesteatoma always associated with mucosal changes within the middle ear cleft.
3. Granulation tissue commonly found in the retrofacial, perisinus, tegmen and mastoid tip cells in squamous COM.
4. Aural polyp is an extensive mucosal disease and may be associated with cholesteatoma .

Recommendation:

The advent of endoscopic evaluation of middle ear cleft preoperatively and intraoperatively will probably provide additional information to our otomicroscopic and surgical findings and reveal the pathology in the mucosal compartments and hidden areas in the middle ear cleft.

There is no conflict of interest

The study is self-funded

REFERENCES

1. Wright T, Valentine P. The anatomy and embryology of the external and middle ear. Gleeson M Scott-Brown's Otorhinolaryngology, Head and Neck Surgery. 2008;3:7.
2. Sanna M. Color atlas of otoscopy: from diagnosis to surgery: Thieme Medical Publishers; 2002.
3. Ballenger JJ, Snow JB. Ballenger's otorhinolaryngology: head and neck surgery: Pmph-usa; 2003.
4. Hildmann H, Sudhoff H. Middle Ear Surgery Springer-Verlag. Berlin; 2006.
5. Gleeson M. Petrous Apex Lesions. In Scott-Brown's Otorhinolaryngology Head and Neck Surgery 2018 Jun 12 (pp. 1317-1324). CRC Press.
6. Browning GG, Merchant SN, Kelly G, Swan IR, Canter R, McKerrows WS. Chronic otitis media. Scotts-Brown's Otorhinolaryngology. Head and Neck Surgery, 7th edition. London: Edward Arnold publisher Ltd. 2008:3395-445.
7. Canter RJ. Acute suppurative otitis media. Scott-Brown's otolaryngology. Butterworths, London. 1997;3(9):1-7.
8. Cummings CW, Bruce H Haughey MDF, Thomas JR, Harker LA, Flint PW, Haughey BH, et al. Cummings Otolaryngology: Head & Neck Surgery: Elsevier Science Health Science Division; 2004.
9. Peter John. Clinical examination of the ears and hearing. In: Gleeson M, Browning GG, Burton MJ, Clarke R, Hibbert J, Jones NS et al. Scott-Brown's Otolaryngology, Head and neck surgery. London: Butterworth- Heinemann 2008. p. 3311-17.
10. HAYNES DS. Clinical Diagnosis. Glasscock-Shambaugh Surgery of the Ear. 2003;1:139.
11. Weber PC. Chronic otitis media. Clinical Otology,. 2007 Aug 8.
12. Bennett M, Warren F, Haynes D. Indications and technique in mastoidectomy. Otolaryngologic Clinics of North America. 2006 Dec 1;39(6):1095-113.

13. Browning GG, Merchant SN, Kelly G. Scott-Brown's Otolaryngology. Head and Neck Surgery Michael Gleason (ed). 1987;3:3395-434.
14. Mills RP. Management of chronic suppurative otitis media. Scott-Brown's otolaryngology. 1997;3:1-1.
15. Chole RA, Sudhoff HH. Chronic otitis media, mastoiditis, and petrositis. Otolaryngology Head and Neck Surgery. Third Ed. Mosby-Year Book, Inc. 1998:3026-46.
16. Laércio M. Cruz O, Kasse CA, Leonhart FD. Efficacy of surgical treatment of chronic otitis media. Otolaryngology—Head and Neck Surgery. 2003 Feb;128(2):263-6.
17. Musaid L, Yousif elamien. Combined approach tympanoplasty in the treatment of chronic suppurative otitis media; Iraqi Board for Medical Specializations in Otolaryngology, Baghdad 1996.
18. Musaid L, Ali Kamal. Surgical findings of chronic suppurative otitis media; Iraqi Board for Medical Specializations in Otolaryngology, Baghdad, 2000.
19. BM B, Katarkar AU, Ambani KP, Bhat TU, Teja TS. Research Article Annals of Otorhinolaryngology-Head and Neck Surgery AOHNS-101. Ann Otorhinolaryngol-Head Neck Surg. 2021.
20. Ebenezer J, Rupa V. Preoperative predictors of incudal necrosis in chronic suppurative otitis media. Otolaryngology—Head and Neck Surgery. 2010 Mar;142(3):415-20.